CLINICAL ORTHOPAEDICS AND RELATED RESEARCH
Number 0, pp. 000–000

VEGF Expression in Osteosarcoma Correlates with Vascular Permeability by Dynamic MRI

Bang H. Hoang, MD; Jonathan P. Dyke, PhD‖; Jason A. Koutcher, MD, PhD†; Andrew G. Huvos, MD‡; Hiroo Mizobuchi, MD‖; Beth Anne Mazza, BS§; Richard Gorlick, MD§; and John H. Healey, MD**

Dynamic enhanced magnetic resonance imaging has been used to assess tumor angiogenesis in osteosarcoma. Recently, vascular endothelial growth factor (VEGF) has been shown to correlate with pulmonary metastasis and a poor prognosis in OS. The purpose of this investigation was to determine whether VEGF expression in OS correlates with vascular permeability detected by dynamic enhanced MRI and to explore the role of dynamic enhanced MRI as a noninvasive means of assessing tumor angiogenic activity. Fifty-five OS patients enrolled in a treatment protocol that included dynamic enhanced MRI. In 15 patients, tumor tissues were available for VEGF immunohistochemical studies. A two-compartment model used the exchange rate constants (k_{ep}) between the plasma and tumor compartments to quantify vascular permeability during dynamic MRI studies. Immunohistochemical staining for VEGF was graded according to the intensity and number of positively stained cells. Vascular endothelial growth factor-positive tumors showed higher mean vascular permeability when compared with VEGF-negative tumors. Vascular permeability also correlated with increasing VEGF expression. The preliminary results in this study demonstrate an association between VEGF and dynamic MR signal enhancement in OS. Dynamic enhanced MRI should be investigated as a means to prognosticate OS patients according to their tumor angiogenic activity.

From the *Department of Surgery, Orthopaedic Surgery Service, †Department of Medical Physics, ‡Department of Pathology, §Department of Pediatrics, Memorial Sloan-Kettering Cancer Center, New York, NY, affiliated with Weill Medical College of Cornell University, New York, NY; and the ‖Department of Radiology, Weill Medical College of Cornell University, New York.
Each author certifies that his or her institution has approved the human protocol for this investigation and that all investigations were conducted in conformity with ethical principles of research, and that informed consent was obtained. Each author certifies that he or she has no commercial associations that might pose a conflict of interest in connection with the submitted article.
B.H.H. is supported by the Biomet Musculoskeletal Oncology Fellowship and the Yurman Limb Preservation Fund. Funding for this project was provided by CA-81832 from the National Cancer Institute, the Foster Foundation, and the Department of Pediatrics at MSKCC.
Correspondence to: Bang H. Hoang, MD, Department of Orthopaedic Surgery, UC Irvine Medical Center, 101 The City Drive, Pavilion III, Orange, CA 92868. Phone: 714-456-5512; Fax: 714-456-7547; E-mail: bhhoang@uci.edu.
DOI: 10.1097/01.blo.0000141492.52166.20

Osteosarcoma, the most common primary malignancy of bone, has a 5-year survival rate of approximately 70% in patients who present with no clinically detectable metastases.[22] The histologic response to preoperative chemotherapy, which may take 2 to 3 months to assess, still is the best predictor of outcome in this disease.[30] Currently, there is a need to stratify patients early according to their potential for disease progression. Despite intensive efforts, however, there are few biologic markers for disease progression.[5,7,8,14,23,24] One candidate, VEGF has been implicated as an important early marker for metastasis in OS.[11]

Vascular endothelial growth factor is a dimeric glycoprotein that induces endothelial cell proliferation and increases permeability of the vascular endothelium.[13,18] Vascular endothelial growth factor modulates both new vessel formation essential for tumor growth and metastasis formation.[15,20] In OS, VEGF expression has been shown to correlate with pulmonary metastasis and a worse prognosis.[11] In addition, circulating VEGF levels by enzyme-linked immunosorbent assay (ELISA) were found to be significantly higher in OS patients who developed pulmonary metastasis.[12] This angiogenic factor clearly emerges as an important indicator of disease progression in OS.

The use of dynamic enhanced MRI in detecting viable tumor in OS has been established.[17,26,27,31] However, the use of dynamic enhanced MRI in estimating VEGF expression in OS has not been investigated. Recently, VEGF expression has been shown to correlate with increased signal enhancement on dynamic enhanced MRI in breast tumors.[16] In addition, an antibody that blocks VEGF function has been demonstrated to suppress vascular permeability seen on functional MRI.[25] This line of evidence indicates that MR signal enhancement can be explored as

a surrogate measure for tumor angiogenesis as reflected by VEGF.

In this study, we examined whether tumor vascular permeability by dynamic enhanced MRI can be correlated with VEGF expression in OS. We hypothesized that measurement of vascular permeability by dynamic enhanced MRI correlates with tumor angiogenic activity as reflected by VEGF expression. Since VEGF expression is predictive of disease progression in OS, dynamic MRI may serve as a noninvasive means to stratify patients early according to their tumor VEGF status.

MATERIALS AND METHODS

From 1998 to 2002, 55 patients with the pathologic diagnosis of OS who were treated at our hospital were enrolled in a treatment protocol that included dynamic enhanced MRI. In 15 of these patients, fresh-frozen tumor tissues were available for immunohistochemical studies. These 15 patients comprised the study population. Fourteen patients with a diagnosis of high-grade OS received systemic neoadjuvant chemotherapy with high-dose methotrexate, cisplatin, and doxorubicin,[21] followed by en bloc surgical resection and postoperative chemotherapy. One patient with low-grade OS had a surgical resection without systemic chemotherapy. All samples were obtained from surgical procedures done at our hospital and collected with informed consent according to an institutional review board approved protocol. Of 15 patients, 5 samples were obtained from biopsy specimens (before chemotherapy) and 10 were obtained from definitive en bloc resection (after neoadjuvant chemotherapy). Dynamic enhanced MRI was done within 3 weeks before definitive en bloc resection. Postoperative chemotherapy was given for 21 weeks after surgery. This study was reviewed and approved by the institutional review board.

The histologic response following neoadjuvant chemotherapy was determined according to the Huvos grading system[30] (Grade 1, 0%-50% tumor necrosis; Grade 2, 51%–90%; Grade 3, 91%–99%; Grade 4, no viable tumor or 100% necrosis). According to this system, each case was categorized as either a good responder (Grades 3 and 4) or a standard responder (Grades 1 and 2).

The protocol for obtaining MRI and analysis was described previously.[4] Briefly, MRI studies were acquired on a 1.5T Signa Horizon or LX scanner (GE, Milwaukee, WI). A standard examination was done including T1-weighted images (400/17) and T2-weighted fat saturated images. The region of interest (ROI) was selected by the radiologist for analysis (Fig 1). Gadopentetate dimeglumine was used as a paramagnetic contrast agent at a concentration of 0.1 mmol/L/kg and a flow rate of 0.8 to 2.0 mL per second, depending on the type of catheter. A 20-mL saline flush was administered after contrast injection to ensure complete mixing of the bolus on delivery. A slower flow rate (0.8–1.0 ml/second) was used in patients with a central venous catheter to prevent damage to the catheter. F1

Dynamic perfusion studies were acquired using a fast multiphase spoiled gradient echo sequence. The entire tumor was covered contiguously with 10 to 12 mm thick sections yielding a toal of five to nine slices, depending on tumor burden. Acqui-

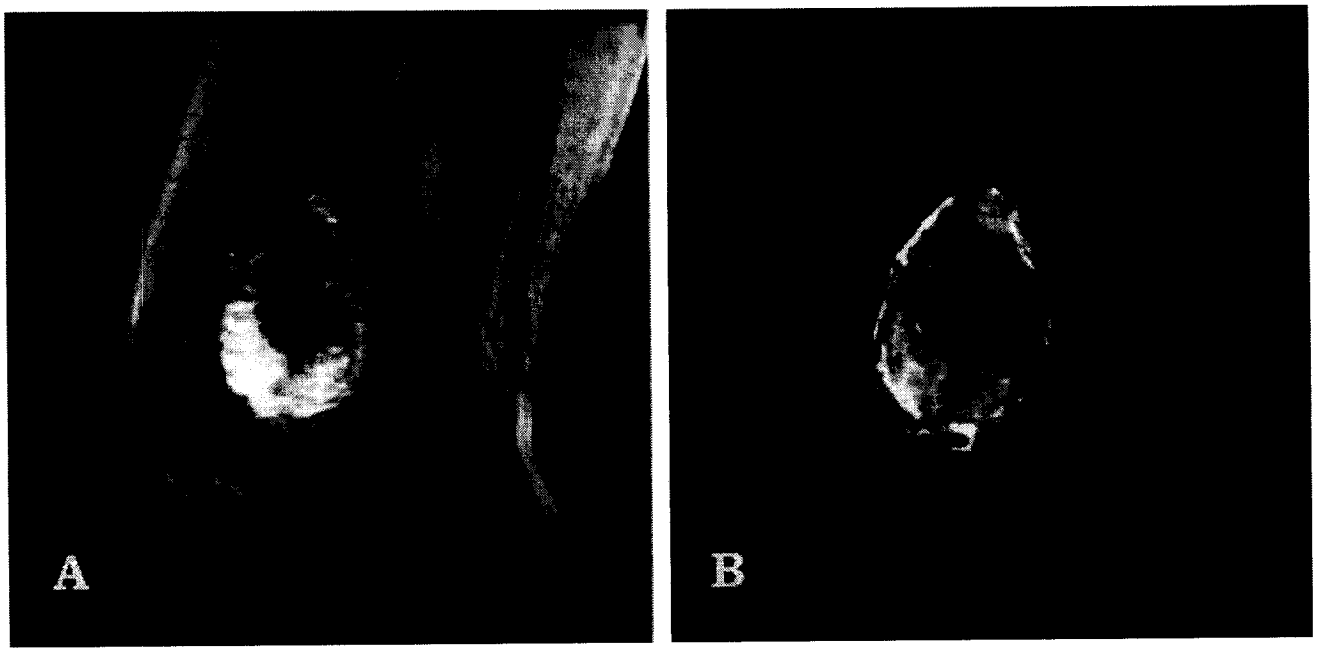

Fig 1 A–B. Dynamic enhanced MRI of a representative distal femoral lesion is shown on (A) an MRI taken after contrast injection and (B) the region of interest selected by the radiologist and mapped for k_{ep}.

sition parameters included a repetition time (TR) of 9 ms; an echo time (TE) of 2 ms; a 30° flip angle, 15.63 kHz receive bandwidth; a 20 to 24 cm field of view; and a 256 × 128 matrix yielding voxel sizes between 12 to 20 mm^3. The central slice was placed parallel to and directly over the long axis of the bone. These parameters provided a temporal resolution between 4.75 and 9.45 seconds per image, which was sufficient to observe the initial uptake of contrast into the ROI. Data were acquired from a total of 20 to 40 time points in scan times of less than 5 minutes. A preliminary scan consisting of five time points ensured adequate signal to noise and exact slice positioning prior to actual gadopentetate dimeglumine administration.

After imaging reconstruction, data were exported to a 1.4 GHz Pentium 4 (Dell, Austin, TX) system for analysis. The software was written to display and analyze the data using interactive data language 5.5 (Research Systems Inc., Boulder, CO). Time intensity curves were analyzed for all voxels within the ROI. One histogram was created that contained a pharmacokinetic model estimate of vascular permeability for each voxel in the tumor. All histograms were normalized to the total number of voxels to account for variability in the size of tumor burden between patients. Histograms used an optimized curve fitting procedure to extract the mean, ampitude, and width of the asymmetric distribution.

The two-compartment model proposed by Hoffman et al[9] based on that of Brix et al[1] contains three parameters: A (signal amplitude), k_{ep} (exchange constant between plasma and tumor compartments in min^{-1}), and k_{el} (elimination constant in min^{-1}) (Fig 2). This allows a correlation between the MRI signal intensity with time and that of vessel permeability on a per voxel basis. The product A × k_{ep} (Ak_{ep}) represents the dynamic enhanced MRI estimate of tumor vascular permeability used in this study.

Immunohistochemical detection of VEGF was done using the ImmunoCruz Staining System (Santa Cruz Biotechnology, Santa Cruz, CA) according to the manufacturer's protocol. Briefly, 4-μm sections were cut from fresh-frozen OS tissues and placed on silane-coated slides. Endogenous peroxidase activity was blocked in phosphate-buffered saline (PBS) containing 0.1% hydrogen peroxide for 5 minutes. Slides were washed in PBS followed by blocking with 10% goat serum-PBS for 20 minutes. A mouse monoclonal antibody for the N-terminus of human VEGF (Santa Cruz Biotechnology) was used as the primary antibody (1:50 dilution). The immunoreactions were visualized with diaminobenzidine as a chromogen and counterstaining was done with hematoxylin. For a negative control, all reagents, except for the primary antibody, were used. Evaluation of VEGF immunoreactivity was done independently by a musculoskeletal pathologist (AGH) who was blinded to the clinicopathologic and dynamic enhanced MRI data. Immunohistochemical staining of tumor cells was classified as 0 (negative), 1+, 2+, or 3+, according the intensity of staining and the number of positively stained cells.

Fisher's exact or chi-square test was done for categorical variables (gender, site of disease, histologic subtype, chemotherapy response). The permeability parameter (Ak_{ep}) value was calculated for each patient. Student t-test was used to compare difference in means. Regression analysis was used to correlate mean Ak_{ep} value with the degree of VEGF staining in tumor tissue. A p value of less than 0.05 was considered statistically significant.

RESULTS

There was no association ($p > 0.1$) between VEGF expression and gender, age, site of disease, or histologic subtype of OS. Of the studied population, there were ten males and five females, ages 7 to 38 years (mean, 20 years) (Table 1). Fourteen patients were diagnosed with high-grade OS and

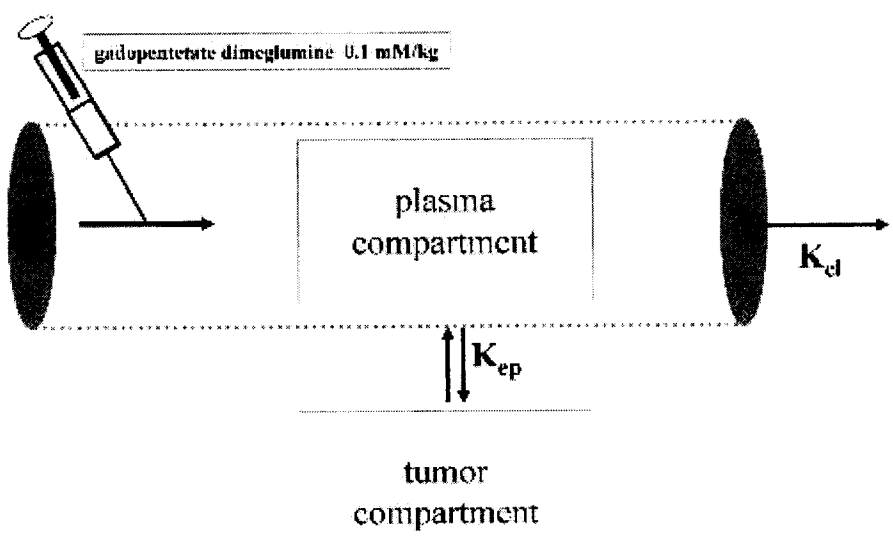

Fig 2. The Brix/Hoffman two-compartment model of vascular permeability is shown. After paramagnetic contrast (gadopentetate dimeglumine) injection, this model used an exchange rate constant (k_{ep} [min^{-1}]) and a constant for contrast elimination (k_{el} [min^{-1}]) to quantify tumor vascular permeability.

TABLE 1. Correlation of Patient Clinicopathologic Data with Tumor VEGF Status

Clinicopathologic Parameter	Total (%)	VEGF Positive	VEGF Negative	P
Number of patients	15	10	5	
Age (years)				
Range	7–38	8–38	13–35	
Mean	21	22	20	0.73†
Gender				
Male	10 (67)	5	5	
Female	5 (33)	5	0	0.18‡
Site				
Distal femur	8 (53)	4	4	
Proximal tibia	4 (27)	4	0	
Proximal humerus	2 (13)	2	0	
Other	1 (7)	0	1	0.15‡
Histological subtype				
Osteoblastic	7 (47)	6	1	
Chondroblastic	3 (20)	1	2	
Other	5 (33)	3	2	0.25‡
Chemotherapy response*				
Good	3 (21)	2	1	
Standard	11 (79)	7	4	0.56‡

*Chemotherapy response was determined by the Huvos grading system (see Materials and Methods) only in high grade OS (n = 14)

†Student's t-test.

‡Chi-square test.

one patient was diagnosed with low-grade OS. All patients with high-grade OS had the same treatment protocols as described previously. The patient with low-grade OS had wide surgical resection without chemotherapy. Most tumors were located in the distal femur (n = 8) or proximal tibia (n = 4). Other sites were proximal humerus (n = 2) and distal tibia (n = 1). The predominant histologic subtype was either osteoblastic (n = 7) or chondroblastic (n = 3). There was no correlation (p = 0.49) between VEGF expression and histologic necrosis after neoadjuvant chemotherapy in this group of patients. Patients with complete histologic necrosis lacked viable cancer tissue upon which to perform the staining, so no statement can be made about VEGF expression in the best responders to chemotherapy.

Overall, patients were grouped according to the degree of tumor VEGF expression. Five of 15 samples showed no detectable VEGF staining. Vascular endothelial growth factor staining was considered positive in the remaining 10 samples (Table 1). In our study, 1+ staining was seen in four samples, 2+ in 4 samples, and 3+ was seen in two samples. In positive OS cells, diffuse VEGF staining was seen in the cytoplasm or membrane or both (Fig 3). No localized nuclear staining pattern was observed in any sample.

In this study, vascular permeability by dynamic MRI appears to correlate with tumor angiogenic activity as indicated by VEGF expression. The mean pharmacokinetic estimate of vascular permeability (Ak_{ep}) was 184.3 min^{-1} for the entire studied group. Analysis of the estimate for vascular permeability Ak_{ep} revealed that VEGF-positive tumors had higher average Ak_{ep} value than VEGF-negative tumors. The mean Ak_{ep} for the VEGF-positive and VEGF-negative tumors were 216.9 min^{-1} and 119.2 min^{-1}, respectively ($p = 0.074$) (Fig 4). In addition, the degree of VEGF staining correlates ($r^2 = 0.92$, $p = 0.042$) with the mean value for Ak_{ep} when tumor samples were stratified into 4 groups (0 or negative, 1+, 2+, 3+ immunostaining) (Fig 5).

DISCUSSION

Angiogenesis, the development of new blood vessels, is an early event in tumor growth and may facilitate tumor progression and metastasis. Vascular endothelial growth factor has emerged as a dominant factor regulating this process in cancer. Also known as vascular permeability factor, VEGF enhances microvessel leakage and exhibits mitogenic activity specific for endothelial cells.[2] This growth factor binds and signals through receptors on endothelial cells that are transmembrane tyrosine kinases.[3,29]

In OS, VEGF may be an important prognostic indicator for disease progression.[11,12] Patients with VEGF-positive tumors have poorer disease-free survival and overall survival compared with those with VEGF-negative tumors.[11] Furthermore, VEGF expression in pretreated OS specimens is predictive of eventual development of pulmonary metastasis.[11] The importance of VEGF in cancer progression also has been validated in other organ systems.[10,19] This growth factor has emerged as an important target for the development of antiangiogenic therapy for cancer.

Currently, methods of assessing tumor angiogenesis depend on the availability of viable tumor tissue from the biopsy specimen or from surgical resection. For various reasons, tumor tissues may not be readily available for these investigations (extensive necrosis from chemotherapy effect or limited biopsy specimens). Therefore, indirect or surrogate measurement of tumor angiogenesis by dynamic enhanced MRI may represent a valuable tool to investigate tumor biology in a clinical setting. This study provides data to support the use of dynamic enhanced MRI to study tumor angiogenesis in human OS by correlating the increase in vascular permeability seen by dynamic enhanced MRI with tumor VEGF expression.

The use of dynamic enhanced MRI in assessing tumor angiogenesis has precedent. This modality has been used to quantify tumor vascular permeability in colorectal cancer[6] and breast cancer.[16] However, the use of dynamic enhanced MRI as a surrogate measure for tumor VEGF

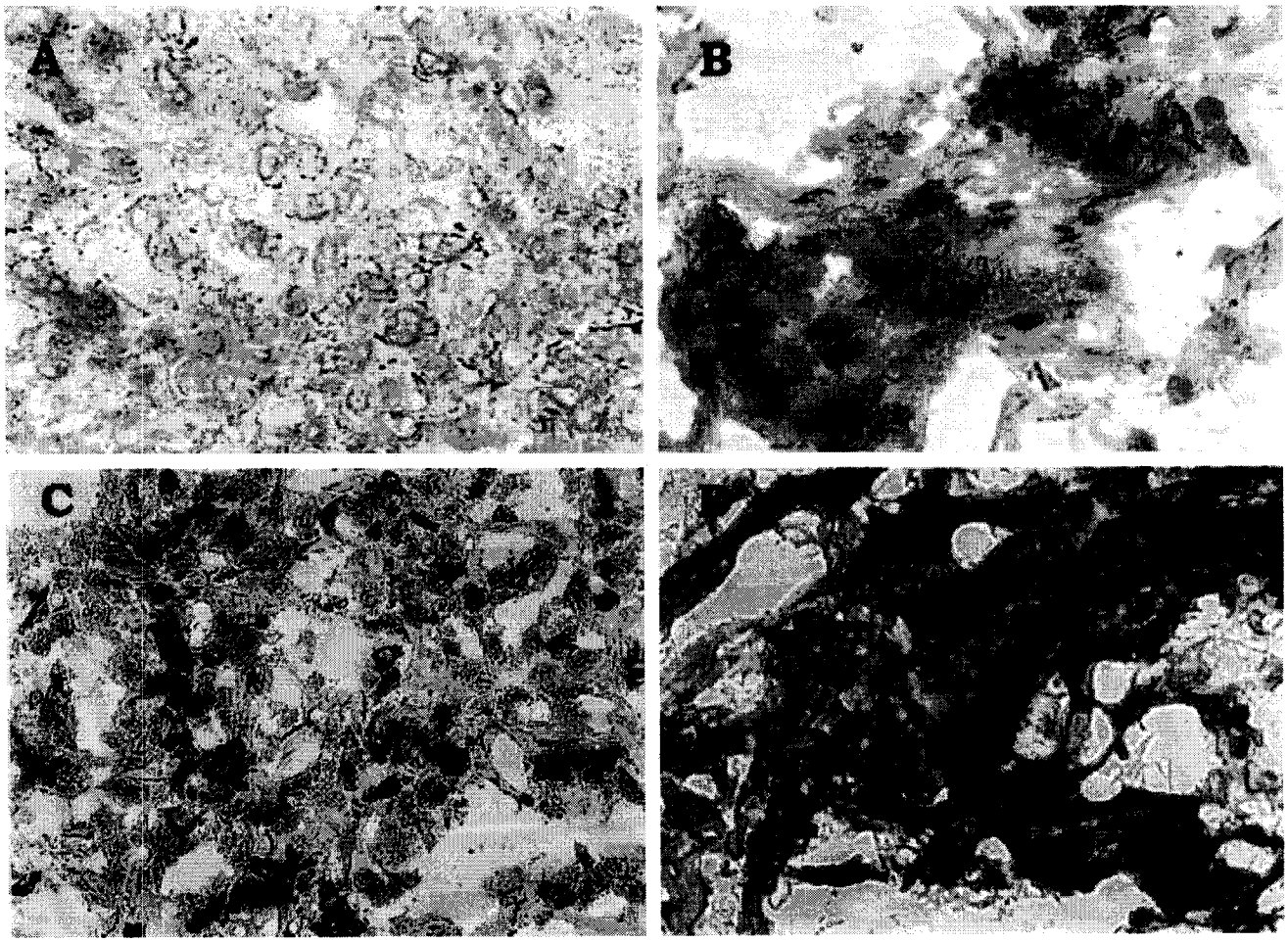

Fig 3 A–D. These photomicrographs show the immunohistochemical analysis for VEGF. Four representative cases are shown. Immunostaining results were graded according to the number of stained cells and intensity of the signal. Slides were examined at x40 magnification under light microscopy. (A) A negative specimen with no staining and samples with (B) 1+, (C) 2+, and (D) 3+ staining, respectively are shown. Control staining was done under the same conditions except that no primary antibody was used.

status has not been reported in bone sarcomas. In this study, there was a significant association between levels of VEGF expression in OS samples and dynamic enhanced MRI permeability, lending support to similar observations made in breast tumors.[16] Several studies have suggested that microvessel density can be correlated with tumor VEGF status.[6,11,16] There are two possible explanations for the higher average Ak_{ep} seen in VEGF-expressing tumors: VEGF-positive tumors may contain higher overall microvessel density resulting in a higher surface area for contrast exchange; or microvessels in VEGF-positive tumors permit more leakage of the contrast agent compared with VEGF-negative tumors. There is evidence in the literature to support both hypotheses in a various tumor systems.[6,16] In OS, VEGF may provide the biologic basis for the apparent increase in vascular permeability seen in tumors expressing this growth factor.

In OS, dynamic enhanced MRI estimate of contrast access (k_{ep}) has been reported as a potential prognostic factor by Reddick et al.[28] In a subgroup with larger tumor size (> 56 cm^2), patients whose tumors showed a higher k_{ep} by dynamic enhanced MRI sustained a correspondingly inferior disease-free survival. Therefore, these investigators proposed using dynamic enhanced MRI as an additional tool for risk stratification in OS. Similarly, the link between dynamic enhanced MRI parameters and VEGF status in the current study suggests that this imaging modality should be validated prospectively as a means to stratify patients with OS according to their tumor angiogenic potential.

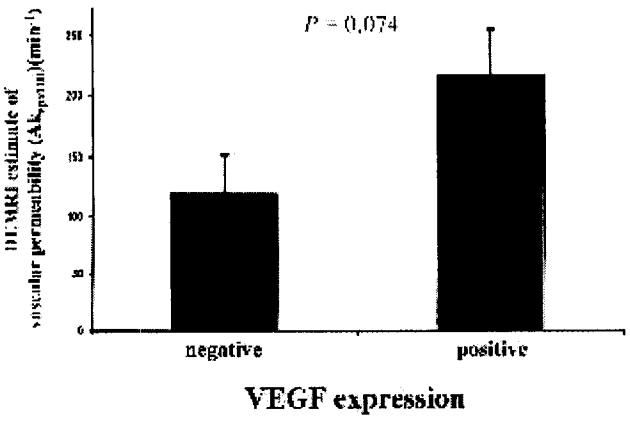

Fig 4. This graph shows the tumor vascular permeability parameter (Ak_{ep}) by dynamic enhanced MRI in VEGF-positive (n = 10) and VEGF-negative (n = 5) samples. Vascular endothelial growth factor positive tumors included samples with 1+, 2+, and 3+ staining.

Our study has three main limitations. First, the number of available samples was small because of a relative paucity of OS cases and the novel nature of dynamic enhanced MRI in a clinical setting. Second, there was no additional validation of tumor VEGF results by using additional markers for angiogenesis in this study (CD34 immunostaining for microvessel density assessment). Third, although the histologic grading for VEGF immunostaining was done by an experienced musculoskeletal pathologist, there was no intraobserver or interobserver validation of the grading criteria in the current study. Future multi-institutional studies using uniformed grading criteria may confirm the validity of such a grading system. Although preliminary, these results should prompt more comprehensive analyses to determine the prospect of using dynamic enhanced MRI as a risk-stratification tool in OS.

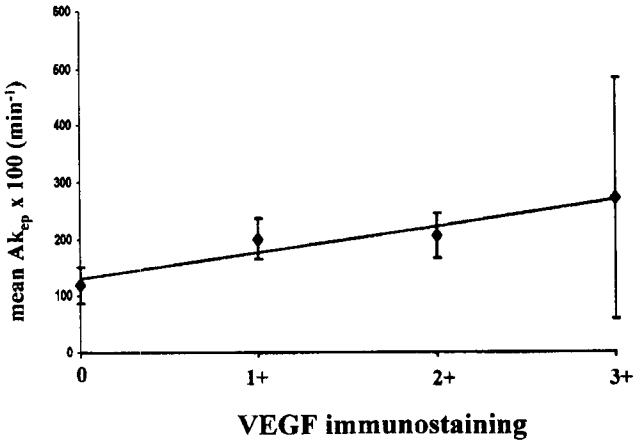

Fig 5. This graph shows the correlation of VEGF expression and tumor vascular permeability. Regression analysis correlating the mean value for vascular permeability (mean Ak_{ep}) with VEGF expression (0 or negative, 1+, 2+, 3+) by immunohistochemistry.

We examined a series of 15 OSs for the expression of VEGF and correlated this expression with model parameters for vascular permeability by dynamic enhanced MRI. The results from this study suggest an important role for dynamic enhanced MRI in assessing tumor angiogenic factor in a noninvasive manner. As such, the physiologic basis of dynamic enhanced MRI as a surrogate measure for tumor neovascularization in OS can be explained partly by tumor VEGF expression. The potential use of dynamic enhanced MRI to stratify OS patients according to angiogenic and metastatic potential of their tumors may be of clinical significance.

Acknowledgment

We would like to thank Dr. Paul A. Meyers for his valuable contribution in recruiting patients and in preparing the IRB protocol for this project.

References

1. Brix G, Semmler W, Port R, et al: Pharmacokinetic parameters in CNS Gd-DTPA enhanced MR imaging. J Comput Assist Tomogr 15:621–628, 2001.
2. Conn G, Soderman DD, Schaeffer MT, et al: Purification of a glycoprotein vascular endothelial cell mitogen from a rat glioma-derived cell line. Proc Natl Acad Sci USA 87:1323–1327, 1990.
3. De Vries C, Escobedo JA, Ueno H, et al: The *fms*-like tyrosine kinase, a receptor for vascular endothelial growth factor. Science 255:989–991, 1992.
4. Dyke JP, Panicek DM, Healey JH, et al: Necrotic fraction estimation of osteogenic and Ewing sarcomas undergoing induction chemotherapy using dynamic enhanced MR imaging. In press. Radiology 228, 2003.
5. Gamberi G, Benassi MS, Bohling T, et al: C-myc and c-fos in human osteosarcoma: prognostic value of mRNA and protein expression. Oncology 55:556–563, 1998.
6. George ML, Dzik-Jurasz AS, Padhani AR, et al: Non-invasive methods of assessing angiogenesis and their value in predicting response to treatment in colorectal cancer. Br J Surg 88:1628–1636, 2001.
7. Gorlick R, Huvos AG, Heller G, et al: Expression of HER2/erbB-2 correlates with survival in osteosarcoma. J Clin Oncol 17:2781–2788, 1999.
8. Guo W, Gorlick R, Ladanyi M, et al: Expression of bone morphogenetic proteins and receptors in sarcomas. Clin Orthop 365:175–183, 1999.
9. Hoffman U, Brix G, Knopp MV, et al: Pharmacokinetic mapping of the breast: a new method for dynamic MR mammography. Magn Reson Med 33:506–514, 1995.
10. Ishigami SI, Arii S, Furutani M, et al: Predictive value of vascular endothelial growth factor (VEGF) in metastasis and prognosis of human colorectal cancer. Br J Cancer 78:1379–1384, 1998.
11. Kaya M, Wada T, Akatsuka T, et al: Vascular endothelial growth factor expression in untreated osteosarcoma is predictive of pulmonary metastasis and poor prognosis. Clin Cancer Res 6:572–577, 2000.

12. Kaya M, Wada T, Kawaguchi S, et al: Increased pre-therapeutic serum vascular endothelial growth factor in patients with early clinical relapse of osteosarcoma. Br J Cancer 86:864–869, 2002.
13. Keck PJ, Hauser SD, Krivi G, et al: Vascular permeability factor, an endothelial cell mitogen related to PDGF. Science 246:1309–1312, 1989.
14. Kloen P, Gebhardt MC, Perez-Atayde A, et al: Expression of transforming growth factor-beta (TGF-beta) isoforms in osteosarcomas: TGF-beta3 is related to disease progression. Cancer 80:2230–2239, 1997.
15. Kim KJ, Li B, Winer J, et al: Inhibition of vascular endothelial growth factor-induced angiogenesis suppresses tumour growth in vivo. Nature 362:841–844, 1993.
16. Knopp MV, Weiss E, Sinn HP, et al: Pathophysiologic basis of contrast enhancement in breast tumors. J Magn Reson Imaging 10: 260–266, 1999.
17. Lang P, Honda G, Roberts T, et al: Musculoskeletal neoplasm: perineoplastic edema versus tumor on dynamic postcontrast MR images with spatial mapping of instantaneous enhancement rates. Radiology 197:831–839, 1995.
18. Leung DW, Cachianes G, Kuang WJ, et al: Vascular endothelial growth factor is a secreted angiogenic mitogen. Science 246:1306–1309, 1989.
19. Maeda K, Chung YS, Ogawa Y, et al: Prognostic value of vascular endothelial growth factor expression in gastric carcinoma. Cancer 77:858–863, 1996.
20. Melnyk O, Shuman MA, Kim KJ: Vascular endothelial growth factor promotes tumor dissemination by a mechanism distinct from its effect on primary tumor growth. Cancer Res 56:921–924, 1996.
21. Meyers PA, Gorlick R, Heller G, et al: Intensification of preoperative chemotherapy for osteogenic sarcoma: results of the Memorial Sloan-Kettering (T12) protocol. J Clin Oncol 16:2452–2458, 1998.
22. Meyers PA, Heller G, Healey J, et al: Chemotherapy for nonmetastatic osteogenic sarcoma: the Memorial Sloan-Kettering experience. J Clin Oncol 10:5–15, 1992.
23. Morris CD, Gorlick R, Huvos G, et al: Human epidermal growth factor receptor 2 as a prognostic indicator in osteogenic sarcoma. Clin Orthop 382:59–65, 2001.
24. Onda M, Matsuda S, Higaki S, et al: ErbB-2 expression is correlated with poor prognosis for patients with osteosarcoma. Cancer 77:71–78, 2001.
25. Pham CD, Roberts TP, van Bruggen N, et al: Magnetic resonance imaging detects suppression of tumor vascular permeability after administration of antibody to vascular endothelial growth factor. Cancer Invest 16:225–230, 1998.
26. Reddick W, Langston J, Meyer W, et al: Discrete signal processing of dynamic contrast-enhanced MR imaging: statistical validation and preliminary clinical application. J Magn Reson Imaging 4:397–404, 1994.
27. Reddick WE, Taylor JS, Fletcher BD: Dynamic MR imaging (DEMRI) of microcirculation in bone sarcoma. J Magn Reson Imaging 10:277–285, 1999.
28. Reddick WE, Wang S, Xiong X, et al: Dynamic magnetic resonance imaging of regional contrast access as an additional prognostic factor in pediatric osteosarcoma. Cancer 91:2230–2237, 2001.
29. Risau W, Flamme I: Vasculogenesis. Annu Rev Cell Dev Biol 11: 73–91, 1995.
30. Rosen G, Caparros B, Huvos AG, et al: Preoperative chemotherapy for osteogenic sarcoma: selection of postoperative adjuvant chemotherapy based on the response of the primary tumor to preoperative chemotherapy. Cancer 49:1221–1230, 1982.
31. Van der Woude HJ, Bloem JL, Hogendoorn PC: Preoperative evaluation and monitoring chemotherapy in patients with high-grade osteogenic and Ewing's sarcoma: review of current imaging modalities. Skeletal Radiol 27:57–71, 1998.